

Scalp problems in the pharmacy

Christine Clark looks at scalp conditions, including dandruff and hair loss

The scalp covers the top of the head and comprises five layers of tissue, the first letters of which conveniently spell scalp:

- **Skin** Skin contains hair follicles, sweat glands, many sebaceous glands, arteries, and veins. The skin of the scalp is relatively thick and is usually hairy.
- **Connective tissue** Connective tissue contains dense fibrous and fatty tissue, arteries, veins, lymphatic vessels and cutaneous nerves. Wounds that penetrate this layer tend to bleed profusely because the dense tissue does not retract and close blood vessels in the way that other tissues do.
- **Aponeurosis** The aponeurosis is a thin (1–2mm thick) tendinous layer.
- **Loose areolar tissue** Loose areolar tissue connects the aponeurosis to the pericranium. It is predominantly vascular.
- **Pericranium** The pericranium is the tissue enveloping the bones of the skull.

Pharmacists are often asked for advice on itchy scalps. Common causes include seborrhoeic dermatitis, contact dermatitis, psoriasis (*PJ*, 21 May 2005, pp622–6), head lice (to be covered in an article later this year) and tinea capitis (scalp ringworm) and, in many cases, various treatments can be recommended.

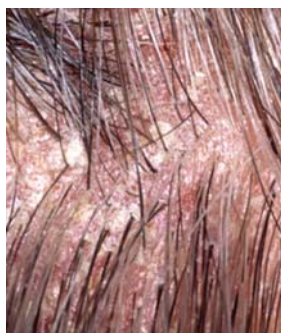Some people, however, simply suffer from a dry itchy scalp, which can be influenced by diet, general health and season. In such cases, pharmacists can give general advice, such as switching to a milder shampoo (eg, a baby shampoo) and washing the hair less frequently.

For many people, loss of hair or other visible scalp conditions can cause immense distress, and sensitivity is required when dealing with these problems.

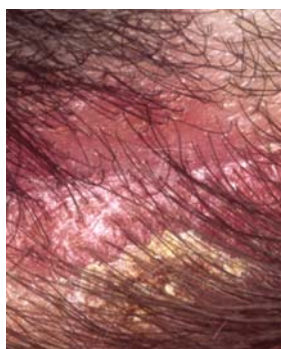
Dandruff and seborrhoeic dermatitis

Dandruff, seborrhoeic dermatitis and cradle cap are all part of the same disorder but they vary in severity and when in life they appear. Dandruff occurs in up to 80 per cent of teenagers and adults and most people are familiar with the symptoms — a scaling scalp that sheds fine, white or grey flakes of dead skin. These are often seen in the hair, close to the scalp, and are visible on the collars and shoulders of dark clothing. Some textbooks use the term “pityriasis capitis” (bran-like scale of the scalp).

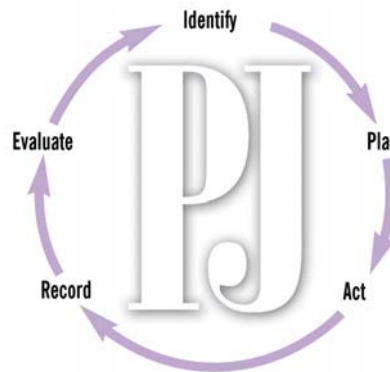
In seborrhoeic dermatitis there is a greater degree of scaling and other body areas can be affected. Dandruff can be the first sign of seborrhoeic dermatitis, but in many cases it does not progress to anything more serious. Seborrhoeic dermatitis is an inflammatory skin disease with a characteristic distribution



Mild seborrhoeic dermatitis



Moderate to severe seborrhoeic dermatitis



Identify knowledge gaps

1. Can you list three active ingredients commonly found in anti-dandruff products and how they work?
2. How is tinea capitis treated?
3. What are the treatment options for hair loss?

Before reading on, think about how this article may help you to do your job better. The Royal Pharmaceutical Society's areas of competence for pharmacists are listed in “Plan and record”, (available at: www.rpsgb.org/education). This article relates to “common disease states” (see appendix 4 of “Plan and record”).

— it is confined to areas that are rich in sebaceous glands (the scalp, the nasolabial folds [the crease that runs from the nose to the corner of the mouth], the ears, eyebrows and eyelashes, the chest area in front of the sternum, and between the shoulders on the back). The lesions are covered with greasy-looking scales and there may be some crusting. The underlying skin can be itchy, red and sore. Differential diagnoses include atopic eczema and scalp psoriasis.

Seborrhoeic dermatitis occurs in at least 3 per cent of the population. It is more common in men than in women and in people with neurological conditions (eg, Parkinson's disease and stroke) or HIV infection. In adults, the condition fluctuates in severity and can persist for years. Seborrhoeic dermatitis occurs as cradle cap in infants under the age of eight months (see Panel 1, p432) but is rarely seen between infancy and puberty.

The exact cause of seborrhoeic dermatitis is unknown but it is strongly associated with the presence of malassezia yeasts (previously known as *Pityrosporum ovale*). These are found in large numbers in sebaceous gland rich areas of all adults. One hypothesis is that the inflammatory reaction is caused by the proliferation of the yeast, which is able to metabolise some components of sebum. An alternative hypothesis suggests that there are normal levels of

Christine Clark, PhD, FRPharmS, is a freelance writer and pharmaceutical consultant

malassezia but an abnormal immune response in the host. Reduction in the yeast population is associated with improvement or elimination of the condition.

Seborrhoeic dermatitis is not contagious or related to diet, but it may be aggravated by illness, psychological stress, fatigue, change of season and reduced general health. Various medicines can worsen or induce seborrhoeic dermatitis, including buspirone, chlorpromazine, cimetidine, gold, griseofulvin, haloperidol, interferon alfa, lithium, methyl-dopa, phenothiazines and psoralen.

Treatment The treatment of dandruff and mild seborrhoeic dermatitis is similar and an extensive range of products is available over the counter for topical use. Active ingredients include zinc pyrithione, selenium sulphate, ketoconazole, coal tar, salicylic acid, and antimicrobial detergents (eg, cetrimide). Some of these ingredients are present in general toiletries (eg, Head & Shoulders contains zinc pyrithione) so pharmacists should ask what shampoos have already been used. The effectiveness of zinc pyrithione, selenium sulphide and ketoconazole appears to be linked to their antimicrobial (ie, antifungal) action whereas coal tar and salicylic acid are keratolytics — they encourage the shedding of dead skin.

Products containing zinc pyrithione or coal tar products, or both, can be recommended as first-line treatments for dandruff or mild cases of seborrhoeic dermatitis. Directions differ, but shampoos are usually used twice a week for two weeks to bring the symptoms under control (this can take up to four weeks with ketoconazole) then less frequently, as necessary for prophylaxis. The lather should be left on the scalp for a few minutes before rinsing. Scalp ointments can be used daily for the first seven days. They are applied and shampooed off after one hour.

The degree of scaling and inflammation can vary between patients. For moderate to severe seborrhoeic dermatitis, ketoconazole 2 per cent shampoo or products containing selenium sulphide can be recommended first line. Ketoconazole is generally better tolerated and it may be marginally more effective. The recurrence rate of the disease is lower after ketoconazole treatment and this is presumed to be because the antifungal accumulates in

Panel 1: Cradle cap

Cradle cap is a patchy, greasy, scaly and crusty skin rash that occurs on the scalp of recently born babies. It is, in effect, infantile seborrhoeic dermatitis that is confined to the scalp. Seborrhoeic dermatitis can also affect other areas of the body, such as behind the ears, in the creases of the neck, armpits and napkin area.

Crusting and scale can be removed by gentle brushing with a soft brush or by massaging with olive oil to soften and loosen the scale then shampooing normally with any baby shampoo. One health visitor has recommended massaging Epaderm into scalp, leaving it on overnight and washing it out in the morning (no shampoo is needed).

However, in most cases cradle cap resolves spontaneously by the age of eight months and pharmacists can reassure anxious parents of this. The cause of cradle cap is not clearly defined but it is not caused by infection, allergy or poor hygiene.

Occasionally, severe cases of cradle cap can distress the infant and may warrant treatment with an antifungal (ketoconazole) shampoo or cream.

the hair. Seborrhoeic dermatitis affecting the scalp and beard area can be treated with shampoos. However, if other areas of the body are affected, ketoconazole cream is the treatment of choice.

Patients using selenium sulphide shampoo should be advised not to apply it for 48 hours before or after colouring their hair or using hair-waving or straightening agents. Those with light, grey or chemically treated (eg, bleached, tinted, permanent-waved) hair, should be advised to rinse their hair for at least five minutes after shampooing to lessen the chance of discoloration.

If the inflammation is severe, short-term use of a topical corticosteroid can be helpful. This controls the inflammation more quickly than an antifungal alone. It is important to remind patients to discontinue the steroid within 14 days (or as soon as an acceptable improvement is achieved) but to continue with the antifungal treatment. Corticosteroids have no effect on the fungal population. Steroid scalp applications listed by Prodigy for the treatment of seborrhoeic dermatitis include betamethasone, hydrocortisone butyrate and mometasone furoate. Clobetasol propionate is considered too potent and not recommended.

Panel 2 lists further advice pharmacists can give.

Tinea capitis

Scalp infections are the most common dermatophyte infections in children worldwide. Scalp ringworm (tinea capitis) is a superficial fungal infection that mainly affects children and is rare in adults. The infection is caused by various dermatophytes, spore-forming fungi that can invade and ingest keratin-rich tissue. The fungi invade deep into the stratum corneum (the outermost layer of skin) or other keratinised skin appendages derived from epidermis, such as hair and nails. They can, however, also be carried on the scalp without invading the skin or hair. One study in schools in south London revealed a tinea capitis prevalence of 2.5 per cent and a carriage rate of 4.9 per cent. Infections are more common in boys than in girls.

Two types of dermatophyte are associated with tinea capitis: anthropophilic (transmitted between humans) and zoophilic (transmitted from an animal host). In the UK and North America the most common causative organism is now *Trichophyton tonsurans*. *Microsporum* species are the second most common. The prevalence of tinea capitis is increasing in the UK, particularly in urban areas and among children of Afro-Caribbean origin. This is believed to be due to anthropophilic spread of *T tonsurans*. A factor that might contribute to the spread is that the organism remains viable on combs, brushes, furniture and bed sheets for long periods.

In general, tinea capitis is characterised by a round, bald, scaly patch on the scalp. The hair can be broken in and around the patch, leaving 3–4mm stumps. Scalps infected with zoophilic species are usually more inflamed

Products for dandruff or seborrhoeic dermatitis

Keratolytics

■ *Coal tar*
Alphosyl 2 in 1 shampoo
Clinitar shampoo, T/Gel therapeutic shampoo,
Pentrax shampoo, Polytar liquid, Psoriderm scalp lotion

■ *Salicylic acid*
Meted shampoo

Antifungals

■ *Ketoconazole*
Dandrazol shampoo,
Nizoral shampoo

■ *Selenium sulphide*
Selsun shampoo

■ *Detergent based*
Betadine shampoo, Ceanel concentrate shampoo,
Dermax shampoo

Combination products

Capasal shampoo (coal tar + salicylic acid), Cocos scalp ointment (coal tar + salicylic acid), Polytar AF shampoo (coal tar + zinc pyrithione), Sebco scalp ointment (coal tar + salicylic acid)

than those infected with anthropophilic species. The first presenting symptoms will usually be small patches of scaly skin with a little hair loss. Once the hair and hair shafts are infected, they are weakened and can break off below the hair shaft, giving the appearance of black dots in the scalp. Patients in whom scalp ringworm is suspected should be referred to their GPs for tests (eg, microscopy and culture of skin scrapings) and antifungal therapy.

Treatment Tinea capitis must be treated with systemic antifungal agents because topical agents cannot penetrate all the infected areas. The length of treatment is determined by the time it takes for infected hair and skin to grow out and this varies according to season. Treatment is deemed successful when culture of skin scrapings from the infected area shows no growth of the organism involved. Systemic antifungal medicines include griseofulvin, itraconazole, ketoconazole, fluconazole and terbinafine. Griseofulvin is effective against *T tonsurans* and *Microsporum* species. Oral ketoconazole and itraconazole are usually avoided because of the risks of liver toxicity and fluconazole is not licensed for this indication. Oral terbinafine is not licensed for use in children but there is wide experience of use for this indication and dosage instructions are given in the British National Formulary for children over the age of one year. Treatment is usually for two weeks.

Griseofulvin is the only licensed treatment for tinea capitis in children of one month and older. An oral daily dose of 1g for up to three months is indicated for adults and 15–20mg per kg for children under 50kg. (Note, this is higher than the dose recommended by Prodigy.) A suspension is available from specialist importers. Griseofulvin has many side-effects that affect about 20 per cent of patients. These include headache and gastrointestinal upset and, more rarely, photosensitivity and lupus-like symptoms. It is contraindicated in several circumstances including severe liver disease and pregnancy — pregnancy should be avoided during and for one month after treatment, and men should be advised not to father children within six months of treatment.

Antifungal shampoos are believed to be useful when used in conjunction with systemic treatment to reduce transmission of the disease through shedding of spores. For the same reasons, some dermatologists recommend treating close contacts who may be asymptomatic carriers. Suitable shampoos are those containing selenium sulphide, ketoconazole or povidone iodine.

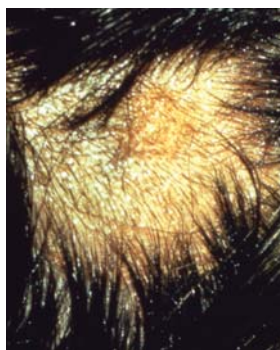
Alopecia

Alopecia (hair loss) can be classified according to whether it is diffuse or localised, and whether or not there is associated scarring.

Androgenic alopecia Androgenic alopecia is the most common type of diffuse alopecia.

Panel 2: Advice for patients with seborrhoeic dermatitis

- Seborrhoeic dermatitis cannot be cured but the condition can be improved and controlled
- Relapse after treatment is common
- Dense scaling can decrease the effect of antifungals so a keratolytic can be used to remove scales before antifungal treatment
- An alternative to a keratolytic is to apply warm olive oil to the scalp for a few hours and then wash with normal shampoo
- Antifungal shampoos can sometimes dry the hair and a moisturising shampoo can be used immediately after or between applications
- Alcoholic products (eg, hair tonics) can irritate inflamed areas
- Soaps and shaving creams can be irritating — emollients can be used as soap substitutes
- Improvement should be seen within seven days of using a topical corticosteroid
- Some products contain peanut (arachis) oil



Tinea capitis is characterised by a round, bald, scaly patch

Although it is also called male-pattern baldness, it can affect women, occurring after the menopause. White men are four times more likely to develop premature balding than black men. By the age of 30 years, 30 per cent of white men have androgenic alopecia and this increases to 50 per cent by the age of 50 years. About half of all women aged 50 years or over will have some degree of the condition, usually seen as a diffuse thinning over the crown of the head. The usual pattern in men is for hair to be lost over the temples before spreading to the crown.

Androgenic alopecia is an inherited condition caused by dihydrotestosterone (DHT). It is believed that DHT reduces the blood supply to hair follicles so individual hairs become thinner, less pigmented and eventually fall out. Drug treatment of androgenic alopecia, aiming to reverse the effects of DHT, is available but is not prescribable on the NHS. Two drugs are licensed: minoxidil and finasteride.

Minoxidil Minoxidil can be purchased over the counter as a topical lotion, in concentrations of 2 per cent (for men and women) and 5 per cent (for men only — the higher strength product can cause hirsutism in women, at remote sites, such as the chin). One millilitre is applied twice a day to the dry hair and scalp. Minoxidil dilates arteries, increasing blood flow to the hair follicles. Although less than 2 per cent of the applied dose is absorbed, patients with cardiovascular disease should be referred to their GPs before treatment.

Minoxidil can only restore existing hair growth and cannot reactivate dead follicles. Early treatment (when the bald patch is no more than 10cm in diameter and still has some residual hair), therefore, gives the best results. About 40 per cent of patients will see some regrowth, which is rarely dense, within 12 months. Patients should be told that hair growth is stimulated only for as long as the agent is used and baldness will quickly recur if treatment is discontinued.

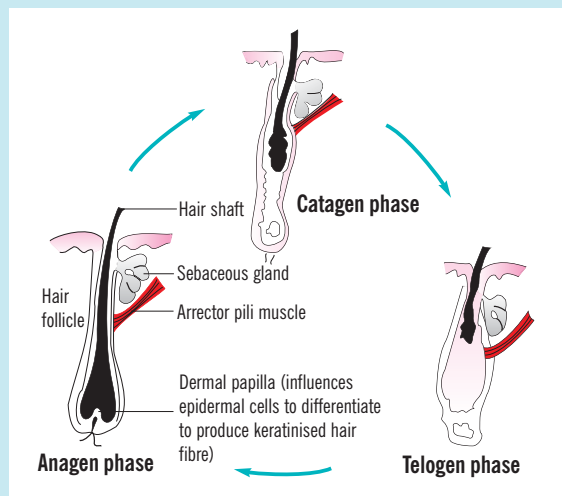
Finasteride Finasteride is an inhibitor of 5-alpha-reductase, the enzyme that metabolises testosterone into DHT. It is an oral treatment that can only be prescribed for men. It is an anti-androgen and, when prescribed to treat male-pattern baldness, the dose is 1mg daily which will produce an effect after between three and six months. Care should be taken to ensure that there is no confusion between this 1mg dose of finasteride (Propecia) and the 5mg dose (Proscar) which is indicated for benign prostatic hyperplasia. The rapid hair fall seen with stopping minoxidil does not occur with finasteride but, if treatment is discontinued, baldness will return within six to 12 months.

Other products A number of other products are claimed to restore hair and treat thinning hair, including Nourkrin, Foltene and Silicium 44. Nourkrin is dietary supplement containing marine, derived polysaccharide

Panel 3: The normal hair growth cycle

Each follicle produces a number of hairs during a lifetime. There are three phases of growth:

1. The **anagen or growth phase** on the scalp lasts between three and five years and the hair grows at approximately 1cm a month. The duration of the anagen phase varies between people and it determines how long the hair will grow if not cut. Usually about 85 per cent of follicles are in the anagen phase.
2. The **catagen phase** follows the anagen phase. It is a transitional stage, lasting two to three weeks during which growth stops and the outer root sheath shrinks and attaches to the root of the hair.
3. The **telogen or dormant phase** lasts about three months. The hair remains in the follicle but does not grow. When the follicle enters the anagen phase and a new hair starts to grow, the old hair is pushed out. Between 25 and 100 telogen phase hairs are shed each day.



and fish extract. One small placebo-controlled trial (n=55) has shown that participants taking the supplement for six months had an average hair growth increase of 37.5 per cent compared with 1.5 per cent in the placebo group. The researchers speculate that the action may be related to an effect on DHT. Foltene and Silicium 44 are both topical products. The former contains a patented mixture of polysaccharides and it is unclear what the active ingredients in the latter product are. There is little evidence for the efficacy of these products.

Other types of diffuse alopecia Diffuse non-scarring alopecia is associated with a variety of endocrine disorders. For example, underactive thyroid, pituitary or adrenal glands can cause the condition, as can an overactive thyroid. Women who are suffering from androgen-secreting tumours will also display male-pattern baldness with virilisation.

Malnutrition can have a detrimental effect on the hair. For example, when the diet lacks sufficient protein, the hair can become dry, brittle and red or pale. Deficiencies of iron or zinc can also give rise to diffuse hair loss.

Telogen effluvium is another form of diffuse alopecia. The telogen phase is the shedding phase of hair growth during which about 50 to 100 hairs are shed daily (see Panel 3). Telogen effluvium is a condition when, instead of the hair follicles being out of phase, in response to an event (eg, high fever, childbirth, surgery and some drugs) they become synchronised so that many hairs are shed at the same time about three months after the event. Other drugs can cause an abrupt cessation of hair growth (anagen effluvium). This effect is well known with cytotoxics and, more rarely, with heparin, warfarin, carbimazole and colchicine. The hair usually begins to grow again if the drug is discontinued.

There is no place for minoxidil or finasteride in pathological hair loss.

Localised alopecia When alopecia is localised, hair loss occurs in patches across the

scalp. In alopecia areata, hair growth usually stops in localised areas. The condition can also affect the beard area and eyebrows. Patients can be as young as their teens, and will have sharply defined bald patches and so-called "exclamation-mark" hairs that are short (0.5cm) and less pigmented than normal and that taper towards the scalp.

Alopecia areata has an autoimmune origin and is fairly common. It is often associated with stress or emotional upheaval. The condition is unpredictable and various outcomes are possible. For example, the patches can enlarge but regrowth of hair after a few months is common. However, the new hair can be white. If the condition reoccurs, more patches are seen, with a slower regrowth of hair. If alopecia areata occurs before puberty, the prognosis is poor. In extreme cases, all the hair can be lost from the scalp (alopecia totalis). Treatment of alopecia areata is not usually successful. Topical steroids and topical immunotherapy have been used with limited success. Minoxidil has also been used.

Trauma to the hair and scalp can also cause patchy hair loss. Causes include: rubbing or pulling the hair constantly, using tight rollers, pulling the hair into a tight bun and using chemicals to straighten, bleach or perm the hair.

Scarring alopecia In scarring alopecia (cicatricial alopecia) hair follicles are destroyed. Hair loss can be diffuse or localised. Causes include chemical burns, thermal burns, irradiation, lichen planus, lupus erythematosus and infections, such as shingles and tertiary syphilis. Again, minoxidil and finasteride are not treatment options.

Action: practice points

Reading is only one way to undertake CPD and the Society will expect to see various approaches in a pharmacist's CPD portfolio.

1. Some patients find coal tar products unpleasant. Look at keratolytic products with your staff. Which are the most pleasant and convenient to use?
2. Make sure you know the directions for using treatments for seborrhoeic dermatitis.
3. Look at the evidence for the efficacy of dietary supplements and other products for hair loss. How would you explain this to a customer?

Evaluate

For your work to be presented as CPD, you need to evaluate your reading and any other activities. Answer the following questions: What have you learnt? How has it added value to your practice? (Have you applied this learning or had any feedback?) What will you do now and how will this be achieved?

Further reading

- Guidance on seborrhoeic dermatitis and fungal skin infections is available from National Library for Health Clinical Knowledge Summaries (<http://cks.library.nhs.uk/>)

Signposting

- The Trichological Society (tel: 08707 666 996; website: www.hairscientists.org)